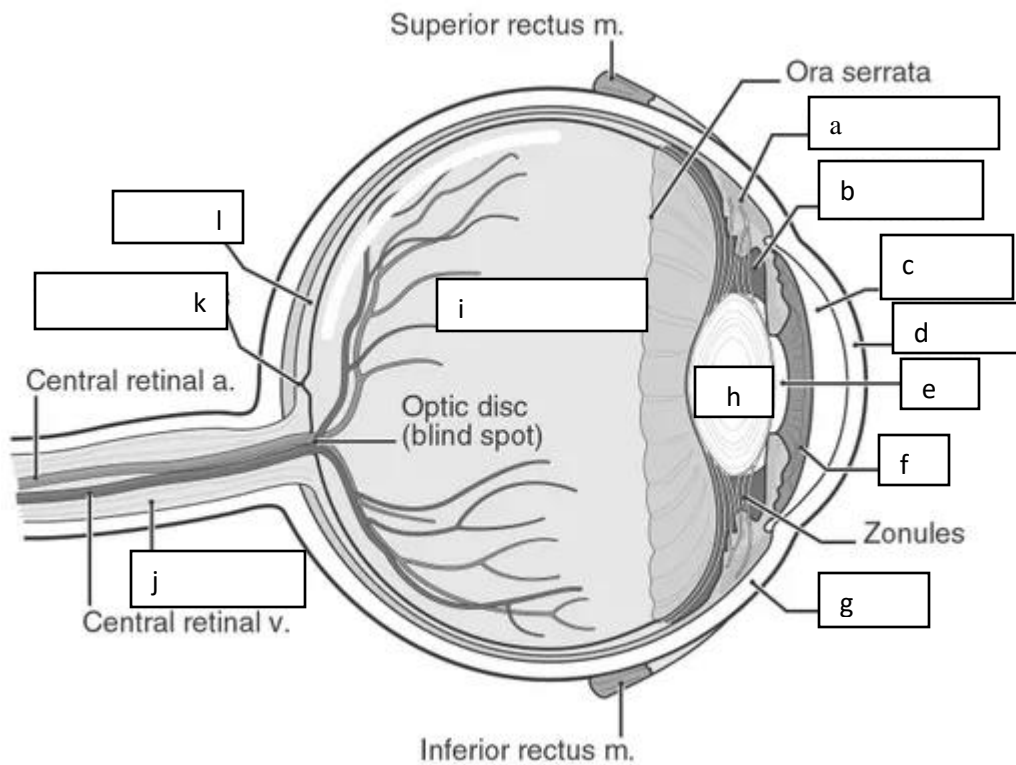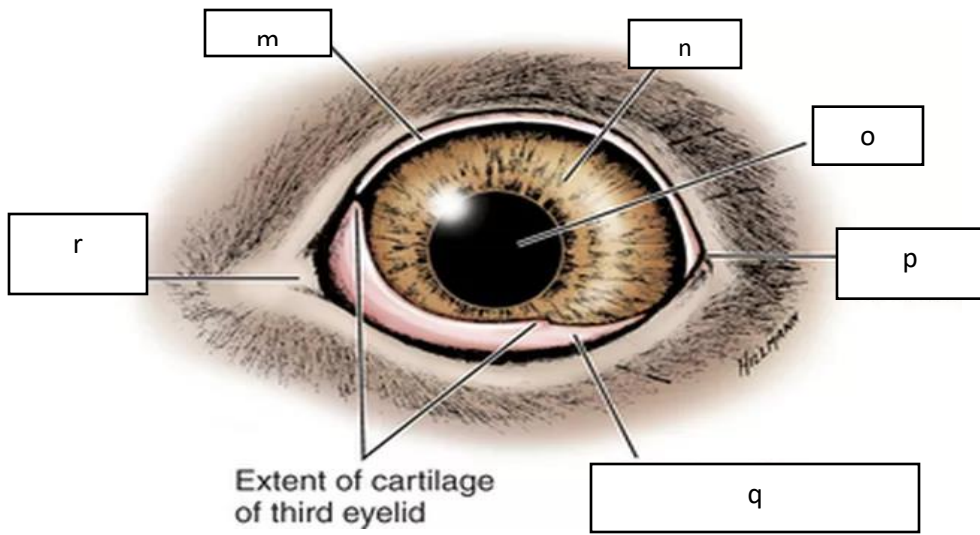
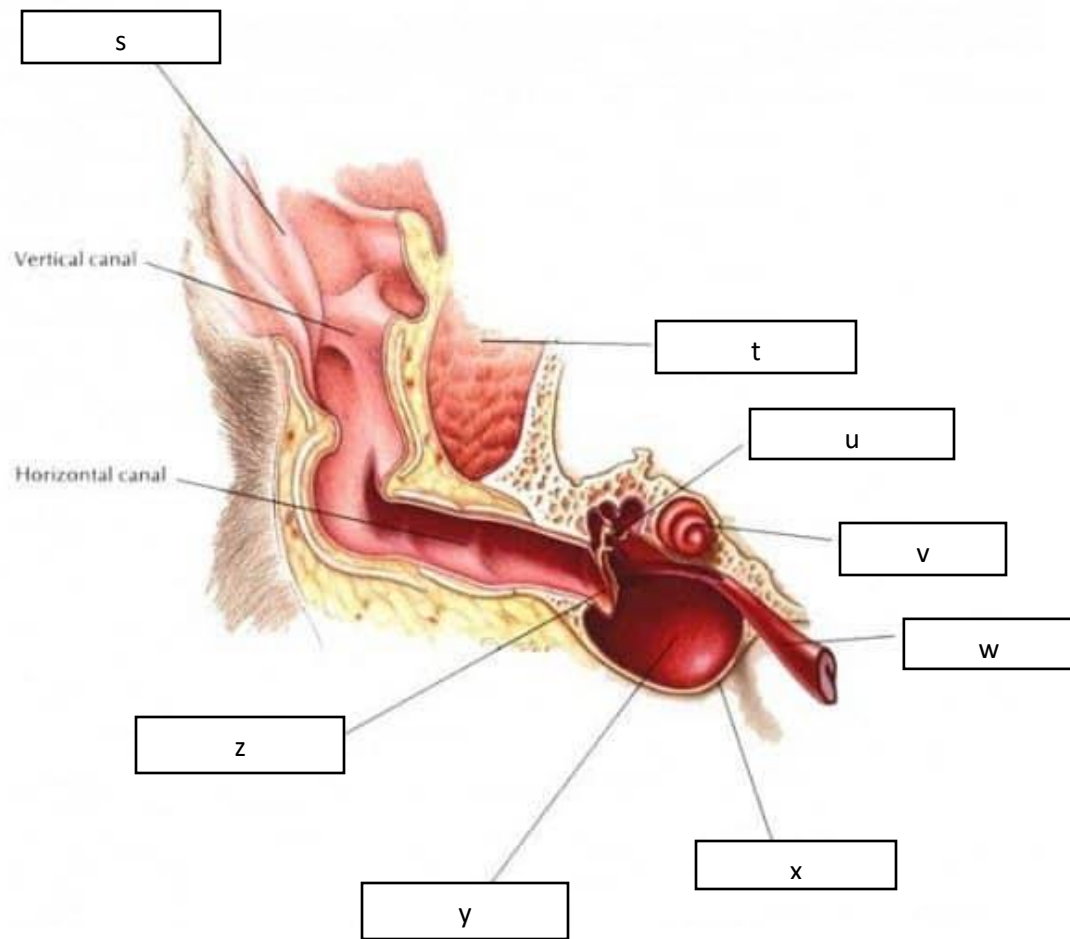


a. ciliary body	d. cornea	g. sclera	j. optic nerve
b. posterior chamber	e. pupil	h. lens	k. fovea centralis
c. anterior chamber	f. iris	i. vitreous body	l. retina



m. sclera	n. iris	o. pupil	p. lateral canthus	q. third eyelid	r. medial canthus
-----------	---------	----------	--------------------	-----------------	-------------------



s. auricular cartilage	u. auditory ossicles	w. auditory tube	y. middle ear cavity
t. temporalis muscle	v. cochlea	x. tympanic bulla	z. tympanic membrane